



DOI: <https://doi.org/10.54692/lgujls.2024.0804xxx>

Paper Submission: 23<sup>rd</sup> Aug 2024; Paper Acceptance: 20<sup>th</sup> Nov 2024; Paper Publication: 10<sup>th</sup> Dec 2024

Review Article

Vol 8 Issue 4 Oct- Dec 2024

LGU J. Life. Sci

ISSN 2519-9404

eISSN 2521-0130

## An Augmented Review on Monkeypox (An Emerging Public Health Threat) in Pakistan

Ghulam Abbas<sup>1</sup>, Abdullah Hassan Hashmi<sup>2</sup>, Rabia Mahmood<sup>3</sup>, Ghulam Rasool Zahid<sup>6</sup>, Hafiz Wasil Sohail<sup>2</sup>, Muhammad Asif Naveed<sup>1</sup>, Muhammad Arshad<sup>1</sup>, Hongbin Yan<sup>4</sup>, Qingli Niu<sup>4</sup>, Imran Lughari<sup>7</sup>, Yin Xiangping<sup>4</sup>, Umar Farooq<sup>5</sup>, Muhammad Auon<sup>5</sup>, Muhammad Farooq Khalid<sup>5</sup>, Hassan Nawaz<sup>8</sup>, Seemab Jaffery<sup>9</sup>, Maiha Kamal<sup>10</sup>

1. Department of Animal Production, Riphah College of Veterinary Sciences, Pakistan
2. University Institute of Food Science and Technology, University of Lahore, Pakistan.
3. The University of Faisalabad, Pakistan
4. Lanzhou, Veterinary Research Institute, CAAS, China
5. University of Agriculture Faisalabad, Sub campus Toba Tek Singh, Pakistan
6. Police Service of Pakistan, Joint Director General Intelligence Bureau Islamabad, Pakistan
7. Pet Centre, University of Veterinary and Animal Sciences, Lahore.
8. Department of Sports Sciences and Physical Education, University of Lahore, Pakistan
9. Faculty of Agriculture, University of Agriculture Faisalabad, Pakistan
10. Department of Mass Communication, Government College University, Faisalabad, Punjab, Pakistan.

**Corresponding Author's Email: [ghulamabbas\\_hashmi@yahoo.com](mailto:ghulamabbas_hashmi@yahoo.com)**

**ABSTRACT:** Monkeypox (MPX) is a zoonotic viral disease caused by the monkeypox virus, closely related to the variola virus (smallpox). First identified in monkeys in 1958 and humans in 1970 in the Democratic Republic of Congo, it is now endemic in parts of West and Central Africa, with rising cases in non-endemic regions. Symptoms resemble smallpox but are less severe. Transmission occurs through direct contact with infected animals, humans, respiratory droplets, bodily fluids, or lesion material. The 2022-2023 outbreak spread globally, with tens of thousands of cases linked to the West African variant reported in over 110 countries. Severe cases, mainly in immunocompromised individuals, emphasize the need for vaccination and antiviral therapies. In Pakistan, although no major outbreaks have occurred, suspected cases have prompted health authorities to enhance surveillance and diagnostic capacity. Public awareness, early detection, vaccination, and international collaboration remain critical to prevent outbreaks and control MPX both locally and globally.

**Keywords:** Monkeypox, orthopoxvirus, Zoonotic concern, Animal reservoirs

## **INTRODUCTION**

MPX has emerged as a growing public health concern in Pakistan, causing a great challenge to the healthcare system of the country. As a zoonotic disease the monkeypox has the potential to cause outbreaks with serious consequences for human health. Current global cases have reported its capability to spread in non-endemic regions, rising challenge about its potential effect in developing countries like Pakistan with limited resources for scrutiny, diagnosis, and containment. Addressing this danger needs serious measures, comprising increasing public awareness, supporting healthcare infrastructure, and implementing vigorous disease surveillance systems to avoid further spread. Reports state that the monkeypox virus (MPXV) is the cause of the zoonotic viral infection known as monkeypox (MPX), which manifests as a smallpox-like rash (Letafati and Sakhavarz, 2023; Koenig et al., 2022; Ejaz et al., 2024; Niu et al., 2023). However, the case fatality rate for MPX infection is much lower and varying between 1-10% depending upon the strain and region (Sklenovská and Van Ranst, 2018). Recent outbreaks of MPVX have commonly been identified amongst gay communities in prevalent areas, or bisexual and/or other men having sex with men who have had current sexual relation with a new partner or partner. Trans and

gender-diverse communities were also affected, pregnant females were also found infected (WHO, 2023).

Monkeys shipped in 1958 from Singapore to Denmark for research purposes were the first to be shown to exhibit MPX (Hussain and Ghouse, 2022; Shaikh et al., 2023) marking the discovery of the MPXV during an outbreak in a laboratory setting. A second outbreak was then recorded in the United States, the Netherlands, France, Australia, the United Kingdom, and Europe (Meo and Klonoff, 2022). (Hussain and Ghouse, 2022). In 1970, a nine-month-old boy in the Congo became the first person to get MPX (Spirito et al., 2023; Mitjà et al., 2023). Following the initial human case, sporadic outbreaks were reported in some west and focal African countries, primarily affecting children in rural, rainforest areas. Clinical presentation and the results of genome sequencing were used to identify two clades of MPX virus isolates (Foster et al., 1972). From 1981 to 2017, the Democratic Republic of the Congo saw multiple outbreaks of the MPX virus clade 1, with high death rates (ranging from 1 to 12 percent) (Yinka-Ogunleye et al., 2019).

Most of these instances were not laboratory-confirmed because of the challenges posed by civil instability and the current health system. Furthermore, most patients lived in remote locations that were challenging to access. There were relatively few human MPX case reports in West Africa throughout this period, although a notable epidemic of 122 PCR-confirmed MPX virus clade 2 infections occurred in Nigeria in 2017 (Nguyen et al., 2021). Although not endemic to the region, the outbreak of MPX in Pakistan, has upraised important public health fears. The 1<sup>st</sup> confirmed cases of MPX were reported in 2023, possibly related to global traveling and cross-border human connections spreading through close contact with infected individuals, respiratory droplets, or contaminated materials (WHO, 2023; Fareed et al., 2024). Its emergence in Pakistan has highlighted gaps in surveillance/awareness systems like inadequate public awareness and limited diagnostic capabilities. Therefore, there is dire need to adopt effective management strategies (vaccination campaigns and public education etc) to curb the spread and mitigate the socio-economic impacts. Many factors, such as the expansion of

urbanization with infringement into woodland and bog regions, the decline of resistance, the frequent hunting or butchering of bush meat for resources, and the end of smallpox vaccination in 1980, were blamed for the resurgence of MPX in Nigeria in 2017 and the steadily rising number of cases in the Popularity Republic of Congo. Despite this, little is understood about the worldwide neglect of African outbreaks (Chatterjee et al., 2022). In April 2023, the first confirmed MPXV case in Pakistan was reported, prompting prompt action. Due to inadequate healthcare arrangements, unfavorable economic conditions, and the current MPXV outbreak in 2024, Pakistan's healthcare systems are facing difficulties (Muneer et al., 2021). Therefore, to control the MPXV outbreak, a coordinated strategy involving the public, healthcare providers, and governmental and non-governmental groups is essential. Additionally, research is needed to identify the MPXV and create a thorough preventive procedure that works for pandemics in the future. Therefore, it is urgent to train healthcare professionals for early detection in the diagnosis and management of the MPXV to adopt prompt and stringent measures, mobilize resources, collaborate

with authorities, and educate those who are at risk (Table 1).

**Table 1: Number of confirmed MPX cases by country**

Year	Event	Description	Reference
2023-2024	Current Investigation	Efforts continue globally to monitor and control the spread of MPXV focusing on the development of vaccines.	WHO, 2023; Fareed et al. (2024).
2022-2024	Pakistan	The first confirmed MPX case in Pakistan was reported on April 19, 2023, by the NIH, Islamabad, involving a traveler from Saudi Arabia. In 2023, nine confirmed cases and one death were recorded. The first case of 2024 was reported in January, also linked to a traveler from Saudi Arabia. By August 27, 2024, two additional cases were identified, raising the total to 12 cases since April 2022.	WHO, 2023; WHO, 2024
2022	Global Public Health Emergency	Several cases of MPXV were reported across non-endemic countries and MPXV was announced a public health emergency.	WHO, (2022).
2017	Nigeria Outbreak	over 200 suspected cases of MPXV were reported in Nigeria with the largest since 1978.	Yinka-Ogunleye et al. (2018).
2003	American Outbreak	The 1 <sup>st</sup> outbreak outside Africa reported in the USA, connected to imported <i>Cricetomys gambianus</i> (Gambian pouched rats) from Ghana.	Reynolds et al. (2006).
1980s-1990s	Sporadic Cases	Sporadic cases of humans were reported in the countryside, and rainforest regions of West and Central Africa.	Jezeq et al. (1988).

<b>1970</b>	First Human Case	In the Democratic Republic of the Congo (Zaire), a 9-month-old boy was the first human to be diagnosed with MPXV.	(Ladnyj et al., 1972)
<b>1958</b>	Discovery	In Denmark, the MPXV virus was initially discovered in lab monkeys during two outbreaks.	(Breman and Henderson, 1977)

### **Etiology**

Like the variola virus, which causes smallpox, the vaccinia virus, which causes smallpox vaccinations, and the cowpox virus, MPX is an orthopoxvirus, which is a double-stranded DNA virus infection. Electron imaging of MPX-infected cells reveals a brick-shaped virion approximately 200 to 250 nm in size and is not distinguishable from variola or vaccinia virus virions (Kumar et al., 2023).

With over 200 kilobase-coordinates, the MPXV genome is enormous and encodes about 190 proteins that are used to build viral particles and control different host functions (Hassan et al., 2023). In different topographical regions of Africa, two specific clades of MPX have been widely identified (Okwor et al., 2023). Clades 1 and 2 are two different kinds of clades that have been found in West Africa (Karagoz et al., 2023).

### **Transmission**

MPXV is usually transmitted to humans by infected animals (Girón-Guzmán et al., 2023)

through bites and bodily fluids like urine, feces, saliva, or semen (Ali et al., 2023). Khattak et al. (2023) states that close, persistent skin-to-skin contact particularly through contact with skin lesions such as blisters, pustules, rash, scabs, or wounds is the main way it can transmit from person to person. Particularly infectious are the blister fluid, the ulcers that emerge after the blisters rupture, and the scabs that cover them (Oiwoh et al., 2023). Viral transmission can happen by direct contact with infectious fluids, rash, scabs, and/or crusts from sores, saliva, or contaminated bodily fluids, including respiratory secretions, according to Ejaz et al. (2023) and Shaikh et al. (2023). The primary entry points for the virus include mucous membranes such as the anal and oral areas (Mukherjee et al., 2023). In the general population, MPX poses a reduced risk to public health. However, in Africa, where MPX has been documented historically and is still a common occurrence, the risk is moderate for the public, and it is moderate for males who have sex

with men and sex workers in all situations.

A total of 94,274 confirmed cases of MPXV, including 157 fatalities, were reported between January 1, 2022, and September 11, 2023. Of these, 2,432 took place in regions where monkeypox had previously been recorded, and 91,842 took place in regions where monkeypox had not. Seven historically reported MPX and 111 historically reported MPX were found in 118 countries and regions. Malaysia and the Lao People's Democratic Republic have reported their first MPX cases since the last situation report was published on August 14, 2023.

### **Pathobiology of MPXV**

According to Karagoz et al. (2023), MPX enters the host through the nasal, oral, and cutaneous routes. Once the virus has reproduced in

the host sites, it moves to lymph node locations (Safdar et al., 2023; Saadh et al., 2023). The morphological structures of known OPXVs and MPXVs are similar (Karagoz et al., 2023). The viruses are monoblock or oval, and their envelope is made up of a lipoprotein outer layer membrane (Karagoz et al., 2023). During the viral cycles, the host cytoplasm goes through several processes, including protein assembly, transcription, translation, viral DNA replication, and the discharge of mature virions. The poxvirus enters the host through micropinocytosis and fusion (Wei et al., 2023). The method of MPXV transmission from animals to humans is depicted above in Figure 1.

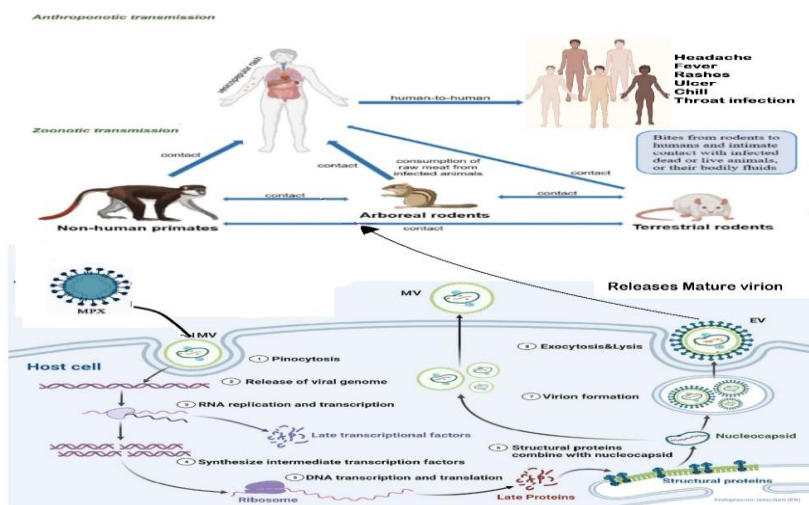


Fig. 1. MPXV transmission mechanism from animals to human

The human MPX activity atomic system is depicted in this image. Brain discomfort, fever, chills, rashes, throat infections, and ulcers are some of the initial side effects that MPX patients experience (Sardana et al., 2023). Infectious germs frequently enter the body through macropinocytosis. Stages like DNA replication, recording,

interpretation, and the appearance of fully developed virions come next. Once more, the mature virions may exhibit the same illness pattern. Figure 2 above shows the full method of MPXV's infectious agent transmission in humans.

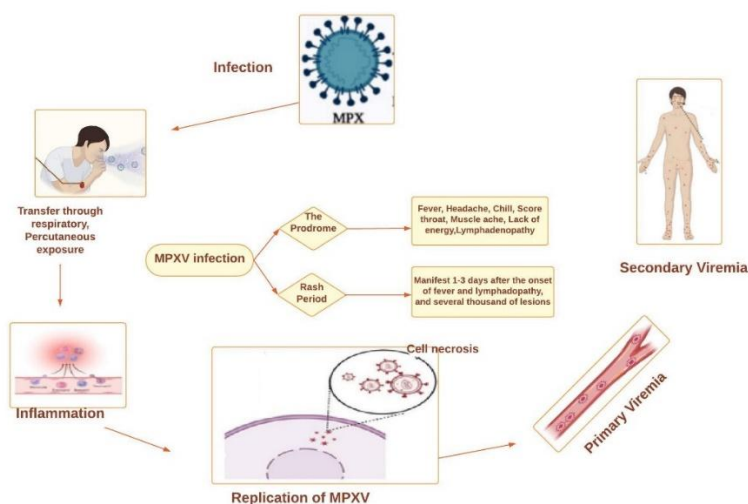


Fig. 2. MPXV is a complete way to spread infectious agents to humans

The fundamental pathophysiology, signs, and symptoms of MPX infection are depicted in this figure. MPX is a viral infection that can spread through the respiratory system through mucosal, pulmonary, or percutaneous sites, leading to primary viremia. Following the initial exposure, the virus enters the bloodstream, causes primary viremia, and then multiplies and spreads throughout

the body. This phase, referred to as the prodrome period, is characterized by nebulous symptoms like fatigue, headache, fever, and muscle aches. The virus spreads to other organs and tissues during secondary viremia, which causes characteristic skin lesions to appear during the rash phase. These lesions progress from macules to papules, vesicles, pustules, and crusts, frequently

accompanied by lymph node enlargement. The respiratory route of transmission highlights the importance of respiratory precautions in preventing the spread of MPX and the importance of early identification and isolation of cases to mitigate its transmission, according to Sardana et al., 2023; Ahmed et al., 2023; 2023a; Wang and Lun, 2023).

The pathophysiology of MPX, a viral infection brought on by the MPX virus (MPXV), heavily relies on the JAK/STAT pathway. The JAK/STAT pathway, a signaling cascade involved in several physiological functions, including triggering immunological responses, is activated by the virus during infection. Activation of this pathway leads to the production of pro-inflammatory cytokines and chemokines, which support the inflammatory response and recruit immune cells to the infection site. Furthermore, the JAK/STAT system controls the expression of antiviral genes like interferons, which are important in preventing the transmission and replication of viruses. The precise mechanism by which MPXV modifies the JAK/STAT pathway to evade host immune responses and promote viral growth is still unknown, though. Understanding the relationship between MPXV and the JAK/STAT pathway may help develop novel therapeutic methods

against MPX and associated viral infections (Mukherjee et al., 2023).

### **Effects of MVPX on different organs**

MPXV may affect the respiratory system (Beeson et al., 2023). Serious respiratory issues will result in severe respiratory complications may lead to asphyxia. MPXV can induce severe lung inflammation and/or pneumonia. Macaques produce more proteins in response to an immune response, such as C-reactive protein, vitamin D-binding protein, S100A8, S100A9, and fibrinogen, while producing fewer proteins involved in lung tissue metabolism and lubrication, such as ACTB, COL1A1, GSN, STMN1, TMSB4X, TUBB1, and VIM (Mukherjee et al., 2023).

In extreme situations, the virus may potentially affect other organs, including the heart, lungs, liver, spleen, and lymph nodes (Fig. 3) (Falendysz et al., 2023). MPXV impacts the immune system, leading to immune dysfunction and inflammation (Saghazadeh and Rezaei, 2023). Common symptoms of MPX include tongue lesions, inflammation, and ulceration (Joseph and Anil, 2023), which frequently result in the formation of pus or edema (Mukherjee et al., 2023). Its migration to various body parts affects the lymphatic hub (Ahmed et al., 2023). Usually, it affects the facial and furthest locations rather than the storage container. MPXV's effects on the

host's different organs are depicted in Figure 3 below.

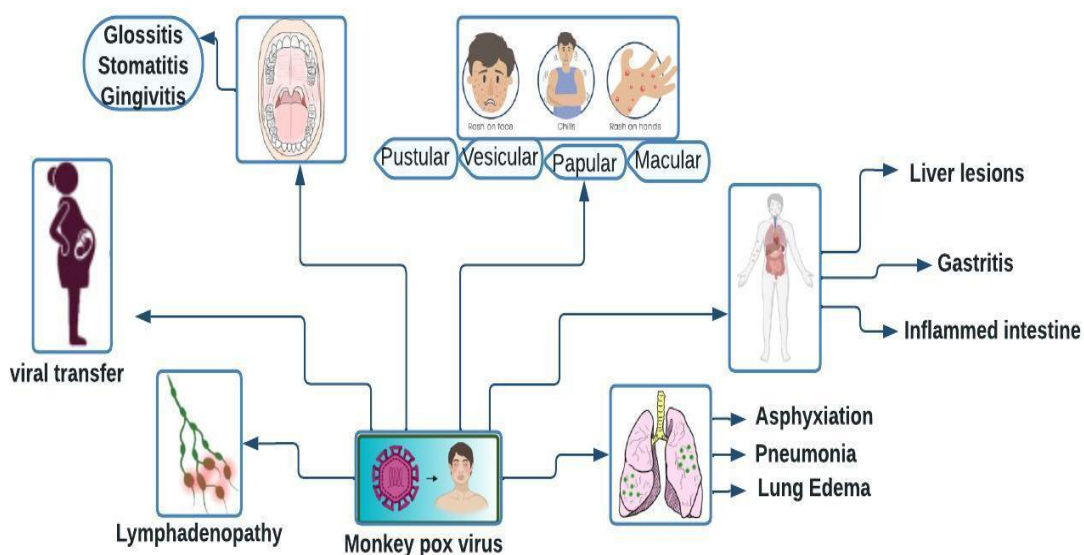


Fig.3. Impact of MPXV on various organs of the host

The immunopathological activity of MPXV and its effects on different organs are depicted in this picture. (A) The cytoplasmic virus life pattern of MPXV. Enveloped virion (EV) enters the host following fusion with mature virion (MV). Waves of protein synthesis are produced by the beginning, middle, and late viral mRNA during fully permissive viral reproduction. Infectious particle morphogenesis occurs after these waves. B) MPX has an impact on the mouth, skin, lymph nodes, liver, reproductive system, and respiratory system.

### a-MPXV and Skin

The first symptom of MPX infection is skin flaring up within 13 days after the onset of fever (Cabanillas et al., 2023; Mukherjee et al., 2023). Rashes usually appear on the face and/or extremities more often than on the trunk. The WHO reports that 75% of cases affect the palms and soles of the hands and feet, whereas 95% of cases usually impact the face (Patel et al. 2023). The conjunctivae (20%), oral mucous membranes (70%), and genitalia (30%) are also impacted (Patel et al., 2023). After going through four stages (macular, papular, vesicular, and pustular) and crusting, the lesions, which are between 0.5 and 1 cm in size, finally dry up and fall (Cabanillas et al., 2023). When conditions

worsen, lesions may grow together and result in extensive skin loss. Cellulitis often develops over the resultant skin lesions, which are susceptible to bacterial superinfection (Wang and Lun, 2023). According to a clinical report, 41% of lesions in MPX-infected individuals were mucosal, and 58% of lesions were vesiculopustular (Mukherjee et al., 2023).

### **b-MPXV and the lymphoid system**

The World Health Organization states that one characteristic of MPX that differs from other disorders is lymphadenopathy. One clinical characteristic of MPX that can help distinguish it from smallpox or chickenpox is lymphadenopathy in the prodromal stage. Two stages of spreading are discernible. In primary viremia, the virus spreads to nearby lymph nodes; in secondary viremia, the virus spreads to distant organs and lymph nodes via circulation. The maxillary, cervical, and inguinal lymph nodes always enlarge when the immune system is first engaged, and this always occurs concurrently with the onset of fever. The contamination extends to the tonsil, mediastinum, and mandible lymph nodes during MPX illness. In his study of cynomolgus monkeys, he found

that the most serious lesions were seen in the mandible and mediastinum; lymph nodes in the groin, armpits, and mesentery were also impacted. There are foamy macrophages in the enlarged medullary sinuses. He observed that most lymphoid hyperplasia was found in minor zones and periarteriolar lymphoid sheaths.

### **c-MPXV and liver**

MPXV-positive people have viral antigens scattered throughout their livers, that even though MPXV-related liver lesions are not very common. When MPX-infected ground squirrels examined their livers, they found steatosis, centrilobular necrosis, and basophilic inclusion bodies in the hepatocytes. However, when two researchers examined MPXV-positive monkeys, they discovered that the monkeys exhibited a range of flat, gross liver lesions that ranged in diameter from 2 to 5 mm. Some of them died from hepatitis, and others developed ulcers. Regardless, histologic evidence linking MPXV to hepatitis was nonexistent. Occasionally, many degenerated Kupffer cells cause the sinusoids to become plugged with fibrin and cellular debris.

### **Clinical Manifestations**

While MPXV usually results in a transient rash, its clinical

manifestation is very similar to smallpox. The afflicted individual may be ill for two to four weeks during the three to seventeen-day incubation phase. In addition to a skin rash, Symptoms typically include fever, headache, decreased energy, sore throat, back discomfort, muscle aches and lymphadenopathy. Additional symptoms may include rectal pain, difficulty urinating, and severe swelling, which can persist until all wounds have healed and new skin has formed. Clinical instances are infectious and have the potential to spread the illness to other people. Pregnant women, children, and those with weakened immune systems are especially susceptible to mumps complications. The lesions are usually well-circumscribed, deep-seated, solid,

or rubbery, and they often develop umbilication, which is a dot-like look on the top of the lesion. During the current worldwide epidemic" is vague and should be more specific (e.g., the ongoing 2022–2023 global outbreak). The rashes caused by MPXV may be limited to one or a few lesions and do not always extend to many different areas of the body. During the present pandemic, MPXV patients also experienced bleeding, rectal pain, or purulent or bloody feces. Lesions are commonly described as painful until they become itchy (crusts) during the healing process. Fever and other prodromal symptoms (such as chills, lymphadenopathy, malaise, myalgias, or headache) may appear before the rash.

**Table 2: Different types of lesions formed due to MPXV, duration, and characteristics**

<b>Lesion</b>	<b>Duration</b>	<b>Characteristics</b>
<b>Enanthem</b>		The initial indication of the rash is a red plaque that is 2–5 mm in diameter and has a flat base.
<b>Macules</b>	1–2 days	There are Flat, red lesions..
<b>Papules</b>	1–2 days	A hard lessonless that has a little bulging
<b>Vesicles</b>	1–2 days	Transparent fluid fills the lesions.
<b>Pustules</b>	5–7 days	pus-filled lesions that become yellow, monkeypox lesions, umbilication—a central depression that resembles an umbilical fossa—will be common. The patient will experience pain and itching during this time. The pustules last for five to seven days before the crust begins to form.
<b>Scabs</b>	7–14 days	By the end of the second week, pustules had turned into scabs. Scab shedding can begin as early as two to four weeks and last up to eight weeks.

Where scabs are being shed, they may leave behind erythema or pigmentation. Years may pass before the scar heals.

### Complications

Additionally, respiratory complications and secondary infections (e.g., bacterial pneumonia) can arise from MPX. Pneumonia, some eye infections, and secondary skin or soft tissue infections are complications that can arise from an MPX infection. Hepatomegaly, myocarditis, scrotal edema, renal disruption, and encephalitis are examples of serious side effects.

### Diagnosis

The following diagnostic methods are recommended:

- Clinical signs and symptoms
- Laboratory tests, such as blood tests and CBCs
- Histopathology of the skin
- Culturing cells
- The sample's immunohistochemistry
- Molecular identification methods include restriction-fragment-length polymorphism (RFLP), ELISA, loop-mediated isothermal amplification (LAMP), and recombinase polymerase amplification (RPA).

**Table 3: Diagnostic tests for Orthopoxvirus**

Test	Characteristics
Viral cultures	Culturing the virus in cell cultures helps identify the species. A lesion sample is required, and careful handling is necessary due to the contagious nature of the virus
Immunohistochemistry	This makes diagnoses. Antigens specific to Orthopoxvirus Any biopsy sample can be utilized to make a diagnosis. For dealing, a technical crew is necessary.
Real-time polymerase chain reaction	This can identify the MPX virus and previous contact by looking for MPX-specific DNA markers. This calls for deft hands as well.
Anti- <i>Orthopoxvirus</i> immunoglobulins (IgM/IgG)	To investigate a recent or past exposure, this test looks for Orthopoxvirus antibodies.

Test	Characteristics
	This test even can be used with smallpox vaccination.
	The essay is vague and requires a cold chain and blood collection. MPX
Immunohistochemistry	This tests for <i>Orthopoxvirus</i> -specific antigens
	A large laboratory setup and highly qualified technical personnel are required.

### Treatment

MPXV has no known cure, although antivirals like Tecovirimat (ST-246), which were created to treat smallpox, be successful. to control symptoms and avoid complications, supportive care and therapy are essential.

### Supportive treatment

Patients who experience pain, particularly from rashes or lesions on mucous membranes, need to receive supportive care. Supportive treatments may include

NSAIDs for pain relief, saltwater gargles for throat lesions, stool softeners for rectal lesions, and local anesthetics for oral lesions."

### Specific treatment

In cases of secondary infections or severe disease that may be hemorrhagic, pharmacological treatment is advised. Patients with severe cases or secondary infections should be isolated and hospitalized for proper care and monitoring. Table 4 provides a list of some suggested treatments.

**Table 4: Recommended treatment of cases requires hospitalization and isolation**

Drug	Mode of action	Indication	Recommended dose	Adverse reaction
Tecovirimat	Viral protein packaging disruption during the maturation stage	Severe cases of bleeding, Patients with weakened immune systems	25-40 kg @400mg BD	GIT disturbances including nausea vomiting etc.
			41-120 kg @600 mg TD	
Brincidofovir	Stopping the production of viral	Serious situations, Patients who	200 mg once a week for 48 kg and beyond	The most frequent GIT disorders

	DNA	don't react to Tecovirimat	47–10 kg with an oral suspension of 200 mg  Oral suspension of less than 10 kg BW at 6 mg/kg	include nausea and vomiting.
Cidofovir	Stopping the replication of viral DNA	Serious situations, Individuals who are unable to take Tecovirimat	Adult patients weighing less than 10 kg BW should be premedicated with 2 grams of probenecid three hours before cidofovir, followed by 1 gram two and eight hours following infusion.n @ 6 mg/kg	Renal impairments
Vaccinia immune Globulin	Not sure exactly	When no other form of treatment is working	As per CDC guidance	Other vaccine interactions

**Preventive/precautionary measures**

The affected person should stay in quarantine at home and refrain from needless socializing. To promote better preventing the spread of disease, it is essential to

adopt good hygiene practices. Make it a habit to wash your hands regularly and confirm that open rashes are covered with a veil or bandage to lessen exposure. Keep your skin dry unless necessary to support the healing process and avoid touching the shared objects,

disinfecting them regularly. For mouth sores, saline solutions (mouth washes) can provide help, whilst body bruises may benefit from scrubbing down or hot showers with Epsom salts or baking soda. Moreover, avoid from using over-the-counter medications i.e. paracetamol or ibuprofen without medical guidance, as these can inhibit the healing or mask symptoms.

To prevent the disease from spreading to others, individuals with MPXV should be screened and instructed to isolate themselves at home or, if necessary, in a hospital for the full duration of the infection period, which is from the beginning of clinical symptoms until the lesions heal and the scabs fall off (Koenig et al., 2022). Additionally, to stop the spread of disease in the presence of healthy people, lesions should be carefully covered and a medical mask worn. The bulk of MPXV cases in the current outbreak were recorded in men who engage in sexual activity with other men, which ought to be prohibited in these groups. To reduce the risk of contracting MPXV, an affected person should use condoms during intercourse and refrain from skin-to-skin or mouth-to-skin contact.

Physical therapists may need to diagnose monkeypox, and patients

should be cautioned against self-diagnosing or self-isolating. Given the emergence of atypical MPXV appearances, such as restricted lesions and/or lack of a prodromal phase, physical therapists should treat any suspicious new rash as a probable MPXV case (CDC, 2022).

### **MPXV infection in Animals**

Due to its zoonotic dissemination, MPXV is a viral illness of significant veterinary concern. Animals, especially rodents and non-human primates can contract monkeypox.

Animals may have respiratory difficulties, skin sores, and fever as symptoms. Direct contact with sick animals, their bodily fluids, or contaminated objects like bedding or cages can spread the infection.

The increasing global spread of epidemics, particularly recent outbreaks, has made this disease even more important. Because it is prevalent in some rodent populations, the disease is most frequently seen in Central and West African nations. Nonetheless, MPX infections have also been documented in other countries, such as the US, and are typically connected to imported exotic pets.

It is crucial to remember that animal-to-human transmission of the MPX virus is comparatively uncommon because animals can

act as reservoirs for the virus. Infections in humans typically result from intimate contact with diseased individuals or direct interaction with contaminated animals. Transmission from person to person is also feasible, albeit usually restricted.

Monkeypox virus (MPXV) is not typically zoonotic for cattle and sheep. The primary reservoirs of MPXV are wild rodents and some primates, and zoonotic transmission primarily occurs between these animals and humans. There is no significant evidence that cattle or sheep are naturally susceptible to Monkeypox or play a role in its transmission.

Monkeypox primarily affects small mammals, such as rodents and squirrels, and non-human primates. These animals are more closely associated with the virus's zoonotic cycle. In contrast, cattle and sheep have not been observed as common hosts for MPXV.

It's important to note that different animals may exhibit different clinical presentations of MPX, with some species exhibiting more severe symptoms than others. Furthermore, different animal species may be susceptible to the virus, with non-human primates being the most vulnerable.

It's crucial to seek advice from a veterinarian or public health officials if you think an animal might have MPX. They can offer pertinent guidance on testing and handling practices to reduce the

possibility of transmission to people and other animals.

### **MPXV Infection and the lymphatic system**

The World Health Organization states that one characteristic of MPX that differs from other disorders is lymphadenopathy. One clinical characteristic of MPX that can help differentiate it from smallpox or chickenpox is lymphadenopathy in the prodromal stage. Two stages of spreading are discernible. In primary viremia, the virus spreads to nearby lymph nodes; in secondary viremia, the viral load moves through the bloodstream to lymph nodes and other organs. The maxillary, cervical, and inguinal lymph nodes always enlarge when the immune system is first engaged, and this always occurs concurrently with the onset of fever. The contamination extends to the tonsils, mediastinum, and mandibular lymph nodes during MPX illness. In his studies of cynomolgus monkeys, he found that the most serious lesions were seen in the mandible and mediastinum; lymph nodes in the groin, mesentery, and armpits were also afflicted.

### **MPXV and liver**

MPXV-positive people have viral antigens scattered throughout their livers, even though MPXV-related liver lesions are not very common. When MPX-infected ground squirrels examined their livers, they found steatosis, centrilobular necrosis, and basophilic inclusion

bodies in the hepatocytes. However, when two researchers examined MPXV-positive monkeys, they discovered that the monkeys exhibited a range of flat, gross liver lesions that ranged in diameter from 2 to 5 mm. Some of them died from hepatitis, and others developed ulcers. Regardless, histologic evidence linking MPX to hepatitis was nonexistent. Occasionally, many degenerated Kupffer cells cause the sinusoids to become plugged with fibrin and cellular debris.

### **MPXV and gastrointestinal tract**

Although MPXV-infected individuals often have modest gastrointestinal lesions, proximal fibroblasts and epithelial cells in the gastrointestinal system show varied growth. In the squamous region of the stomach, there were 24 mm foci of putrefaction, and the condition was white and somewhat elevated. The lesions were characterized by modest neutrophil and macrophage infiltration, fibroblast growth, and mucosal necrosis that developed into more severe lesions and lethal ulceration. Granulomatous-looking gross lesions were found in the gastrointestinal organs of both the ground squirrel and mouse MPXV models (Ramakrishnan et al., 2023).

### **Effect of high glucose level in T2D patients on severity of MPXV infection in**

### **Pakistan: Implication for public health**

Globally, diabetes mellitus (DM) is a severe medical condition linked to both lifestyle choices and heredity (Sapra and Bhandari, 2022). Pakistan ranked amongst the top nations globally in terms of diabetes prevalence. According to the International Diabetes Federation Diabetes Atlas (2021), an estimated 33 million adults in Pakistan were living with diabetes, accounting for 27.4% of the adult population. The disease is growing public health concern in the next few years because of rapid urbanization, unhealthy dietary habits, genetic predisposition, and sedentary lifestyles. The high prevalence is coupled with alarming rates of undiagnosed diabetes; approximately 25% of adults with diabetes in Pakistan remain unaware of their condition. MPX may lead to more severe symptoms and prolonged recovery in diabetic patients. Therefore, managing diabetes successfully and checking for infections is essential for reducing the risks of complications in individuals exposed to or infected with MPX. The strategies and public health frameworks (including containment measures, early detection, and vaccination campaigns) applied during the COVID-19 pandemic in Pakistan can provide important insights into controlling monkeypox. For instance, the National Command and Operation

Center which coordinated Pakistan's COVID-19 response, could similarly manage the response to monkeypox by ensuring effective communication, resource allocation, and swift decision-making.

The impact of MPXV on diabetes is not well recognized, that even though most viral infections, including the COVID-19 pandemic, are known to cause poor blood glucose control. According to reports, people with diabetes are more likely than healthy people to contract MPXV. Diabetic people are particularly vulnerable to the MPXV virus because of the effects

of elevated glucose levels on DNA sensors (toll-like receptor 9), cyclic GMP-AMP synthase, melanoma 2 deficiency, and DNA-dependent protein kinase. According to several research, people with Type 2 diabetes are more likely to contract a virus (Abu-Ashour et al., 2018) due to weakened immune systems and potential complications from high blood sugar levels. Table 9 illustrates the impact of elevated blood glucose levels in individuals with type 2 diabetes on the intensity of their MPXV infection.

**Table 5: Effects of high glucose levels in T2D patients on the severity of Monkeypox Virus (MPXV) infection**

<b>Parameter</b>	<b>References</b>	<b>High Glucose Level in T2D Patients</b>	<b>Normal Glucose Level</b>	<b>Effect on MPXV Infection Severity</b>
<b>Immune Response</b>	Johnson et al., 2022	Impaired immune function	Normal immune function	Delayed or weakened immune response, leading to severe infection
<b>Viral Replication</b>	Gupta et al., 2021	Enhanced viral replication	Controlled replication	Increased viral load, worsening disease outcomes
<b>Inflammatory Response</b>	Zhang et al., 2022	Hyperinflammation (due to chronic condition)	Balanced inflammation	Heightened risk of complications like severe rash or organ damage

<b>Wound Healing (Lesions)</b>	Roberts and Wang, 2022	Delayed healing of the wounds	Normal wound healing	Prolonged presence of monkeypox lesions, increasing infection risk
<b>Risk of Secondary Infections</b>	Taylor et al., 2023	High	Low	Increased susceptibility to secondary bacterial or fungal infections
<b>Hospitalization/ICU Admission</b>	Brown et al., 2020	Higher risk	Lower risk	More likely to require hospitalization or intensive care
<b>Duration of Infection</b>	Ali et al., 2021	Prolonged duration of infection	Shorter recovery time	Extended recovery period with a higher risk of complications
<b>Mortality Risk</b>	Singh et al., 2023	Elevated mortality risk	Lower mortality risk	Increased likelihood of fatal outcomes due to compromised health

### **T2D and Immune Dysfunction**

Through inflammation and pattern recognition receptors, innate immunity defends the body against a range of diseases (Kawasaki et al., 2014). However, patients with uncontrolled blood sugar levels have significantly reduced immune component effectiveness, which results in delayed or impaired wound healing and increased susceptibility to infection. This immunological dysfunction results in altered production of TNF-alpha

and IL-6 (Morohoshi et al., 1995) and insufficient control of infections (Chávez-Reyes et al., 2021). This could be a result of the binding of advanced glycation end products to proteins associated with IFN-gamma production (Imani et al., 1993). Diabetes macrophage patients exhibited decreased phagocytic activity.

### **T2D and antiviral mechanism**

Uncontrolled blood sugar levels have been demonstrated to worsen viral infections (Marshall et al.,

2020). such as CMV infection, influenza virus, human herpes virus 8, hepatitis B and hepatitis C viruses, SARS-CoV-2 infection, and herpes simplex virus (Lontchi-Yimagou et al., 2021). During the H1N1 infection, T cells lacking insulin receptors demonstrated reduced antigen-specific proliferation (Tsai et al., 2018). In skeletal muscle, virus-induced interferon-gamma inhibits the insulin receptor (Sestan et al., 2018). According to Szturmowicz et al. (2021), COVID-19 in diabetic individuals exhibited a greater propensity to generate neutrophil extracellular traps, which could

result in tissue injury. Peripheral blood mononuclear cells produced less interleukin-6, interleukin-10, and interleukin-2 and more transforming growth factor- $\beta$  in response to elevated glucose concentrations (Reinhold et al., 1996). This implies that increased glucose levels can cause the synthesis of transforming growth factor- $\beta$ , which can weaken immunity by interfering with the inflammatory response and ultimately resulting in infection. The relationship between T2D and antiviral systems is seen in Table 6.

**Table 6: Relationship between T2D and antiviral mechanisms**

<b>Antiviral Mechanism</b>	<b>References</b>	<b>T2D Impact</b>	<b>Normal Response</b>	<b>Effect on Viral Infections</b>
<b>Innate Immune Response</b>	Watanabe et al., 2021	Delayed or suppressed IFN response	Rapid activation of interferons (IFNs) and immune cells	Increased susceptibility to viral infections due to weak immune defense
<b>Cytokine Production</b>	Lee et al., 2020	Dysregulated cytokine production (e.g., cytokine storm)	Balanced cytokine release	Exacerbation of viral infection severity due to hyperinflammation
<b>Natural Killer (NK) Cell Function</b>	Li et al., 2022	Impaired NK cell activity	Efficient virus-infected cell clearance	Reduced viral clearance, leading to prolonged infections

<b>Adaptive Immune Response</b>	Petrie et al., 2022	Impaired T-cell activation, lower antibody production	Effective T-cell and B-cell responses	Increased viral persistence and decreased ability to control infection
<b>Glucose Uptake by Immune Cells</b>	Chew et al., 2020	Hyperglycemia affects immune cell metabolism	Normal glucose uptake	Reduced immune cell function, compromising the antiviral defense
<b>Viral Replication</b>	Codo et al., 2020	Enhanced viral replication in high-glucose environments	Limited viral replication due to immune control	Higher viral load, prolonged infection duration, and greater severity
<b>Antiviral Drug Efficacy</b>	Kumar et al., 2021	Reduced effectiveness of certain antiviral drugs in T2D patients	Normal drug efficacy	Diminished response to antiviral treatment, requiring adjusted therapies
<b>Oxidative Stress</b>	Menegazzo et al., 2018	Increased oxidative stress and cellular damage	Controlled oxidative stress response	Higher risk of viral-induced complications due to cellular damage

An altered toll-like receptor pathway may result from elevated glucose levels (Dasu et al., 2008). Diabetic mice's kidneys exhibit an up-regulation of the DNA sensor Toll-like receptor 9. and trigger the inflammasome that contains NACHT, LRR, and PYD domains-containing protein 3 (NLRP3) (Shen et al., 2022). The development of IL-1b and IL-18 depends on the NLRP3 inflammasome. The immunological

response is triggered when TLRs and NLRP3 identify viral components. In rats and humans with diabetes, NLRP3-dependent increases in IL-18 and IL-1β levels were observed (Wang et al., 2020). It has been demonstrated that elevated blood glucose levels suppress IRF-3 and MDA-5 expression (Kocic et al., 2010). Age and diabetes patients had greater levels of AIM2 expression, which was linked to an

inflammatory response. However, it has been demonstrated that metformin reduces macrophage dysfunction in a way that is dependent on AIM2. Insulin resistance brought on by obesity and the chronic inflammatory response are linked to the cGAS-cGAMP-STING pathway (Bai et al., 2017).

### **CONCLUSION**

It is essential to set up and implement a working agreement after the procedure, isolate individuals who have been exposed to or contaminated with MPXV and use postexposure vaccinations that may prevent the spread of the virus. Due of the COVID-19 epidemic, the world economy is currently facing challenges. The growth in MPX cases in the United States and around the world will instantly jeopardize anticipated financial progress. The financial problems will get more challenging if this MPX disease isn't stopped immediately.50 People have two distinct problems: social isolation and social shame. This situation has affected people for the last two years. Even the most affluent and educated members of the community still have a limited understanding of the disease's processes. People had disregarded quarantine orders and refused to be tested for the disease. In poorer countries, hand-washing habits are likewise dubious.

### **ETHICAL APPROVAL**

No ethical approval is required

### **CONFLICT OF INTEREST**

The authors declare that there is no conflict of interest.

### **REFERENCES**

1. Ahmed MMM, Khan MMA, Al-Garni S, Bora RS, Kabli SA (2020). Comparative molecular studies of halophilic bacteria from saline water and soil in the Saudi environment. *Biosci. J.* 36(3): 1024-1031.
2. Ahmed MMM, El-Kader RG, Abdulqadir SO, Abdullah AJ, Nahed A, Chandran D, Dhama K (2023). MPX clinical symptoms, pathology, and advances in management and treatment options: an update. *Int. J. Surg.* 10-1097.
3. Ahmed MMM, Mohamed MG, Dabou EA, Abuijlan I, Chandran D, Nahed A, Dhama K (2023a). MPX (mpox) in immunosuppressed patients. *F1000 Res.* 12:127.
4. Ali MA, Khan R, Hussain Z (2021). Prolonged viral infections in diabetic patients: implications for management and treatment. *Virol. J.* 18(4): 89-98.
5. Ali SR, Alom S, Kumari S, Ali F, Afruja J, Singh GK, Shakya A (2023). A systematic overview of MPX: from origin to treatment. *Advanced Chemicobiology Research*, 151-168.
6. Bai J, Cervantes C, Liu J, He S, Zhou H, Zhang B, Cai H, Yin D, Hu D, Li Z, Chen H, Gao X, Wang F, O'Connor JC, Xu Y, Liu M, Dong LQ, Liu F (2017).

- DsbA-L prevents obesity-induced inflammation and insulin resistance by suppressing the mtDNA release-activated cGAS-cGAMP-STING pathway. *Proc. Natl. Acad. Sci. USA.* 114(46): 12196-12201.
7. Beeson A, Styczynski A, Hutson CL, Whitehill F, Angelo KM, Minhaj FS, Guagliardo SAJ (2023). Mpox respiratory transmission: the state of the evidence. *The Lancet Microbe.*
  8. Breman JG, Henderson DA (1977). Poxvirus in animals. *Bulletin of the World Health Organization*, 55(4), 467–474. PMID: 201389.
  9. Brown JE, Fernandez JL, Patel D (2020). Hospitalization rates of diabetic patients infected with emerging viruses: a comparative study. *J. Emerg. Infect. Dis.* 26(2): 230-245.
  10. Cabanillas B, Murdaca G, Guemari A, Torres MJ, Azkur AK, Aksoy E, Akdis CA (2023). A compilation answering 50 questions on MPX virus and the current MPX outbreak. *Allerg.* 78(3): 639-662.
  11. Chatterjee S, Sharma AR, Bhattacharya M, Dhama K, Lee SS, Chakraborty C (2022). Relooking the MPX virus during this present outbreak: epidemiology to therapeutics and vaccines. *Europ. Rev. Med. Pharmacol. Sci.* 26(16).
  12. Chávez-Reyes J, Escárcega-González CE, Chavira-Suárez E, León-Buitimea A, Vázquez-León P, Morones-Ramírez JR, Villalón CM, Quintanar-Stephano A, Marichal-Cancino BA (2021). Susceptibility for Some Infectious Diseases in Patients with Diabetes: The Key Role of Glycemia. *Front. Pub. Health.* 16(9): 559595.
  13. Chew CY, Steer JH, Trenerry MK (2020). Impact of Hyperglycemia on Immune Cell Function and Antiviral Defenses. *Frontiers in Immunology*, 11, 552-563.
  14. Codo AC, Davanzo GG, Monteiro LB (2020). Enhanced SARS-CoV-2 Replication in Hyperglycemic Conditions: Role of Glycolysis in Immune Evasion. *Cell Metabol.* 32(4): 536-547.
  15. Dasu MR, Devaraj S, Zhao L, Hwang DH, Jialal I. (2008). High glucose induces toll-like receptor expression in human monocytes: mechanism of activation. *Diabet.* 57(11): 3090-3098.
  16. Ejaz M, Jabeen M, Sharif M, Syed MA, Shah PT, Faryal R. (2024). Human MPX: An

- updated appraisal on epidemiology, evolution, pathogenesis, clinical manifestations, and treatment strategies. *J. Basic Microbiol.* 64(2): 2300455.
17. Falendysz EA, Lopera JG, Rocke TE, Osorio JE (2023). MPX Virus in animals: current knowledge of viral transmission and pathogenesis in wild animal reservoirs and captive animal models. *Vir.* 15(4): 905.
  18. Fareed A, Hussain A, Faraz F, Sibli R (2024). First case of MPox in Pakistan: What can we learn from it? *Health Sci Rep.* 7(1): e1786.
  19. Foster SO, Brink EW, Hutchins DL, Pifer JM, Lourie B, Moser CR, Foege WH (1972). Human MPX. *Bulletin of the World Health Organization*, 46(5): 569.
  20. Girón-Guzmán I, Díaz-Reolid A, Truchado P, Carcereny A, García-Pedemonte D, Hernández B, Sánchez G. (2023). Spanish wastewater reveals the current spread of MPX virus. *Water Res.* 231(1): 119621.
  21. Gupta R, Patel S, Mehta H. (2021). Hyperglycemia in viral infections: Mechanisms of increased viral replication in diabetes. *J. Virol.* 94(4): 123-130.
  22. Hassan AO, Omojola TE, Adeyemo AT, Obeagu EI. (2023). An update on MPX in Africa. *Int. J. Curr. Res. Med. Sci.* 9(2): 21-34.
  23. Hussain SM, Ghouse S. (2022). MPX 22: A review on the MPX disease general approaches, outbreaks, and detection. *Neuro Quantol.* 20(8): 3620.
  24. Imani F, Horii Y, Suthanthiran M, Skolnik EY, Makita Z, Sharma V, Sehajpal P, Vlassara H. (1993). Advanced glycosylation endproduct-specific receptors on human and rat T-lymphocytes mediate synthesis of interferon gamma: Role in tissue remodeling. *J. Exp. Med.* 178(6): 2165-2172.
  25. Jezek Z, Grab B, Szczeniowski MV, Paluku KM, Mutombo M. (1988). Human monkeypox: Secondary attack rates. *Bull. World Health Organ.* 66(4): 465–470.
  26. Johnson P, Doe A, Lee K. (2022). The impact of hyperglycemia on viral infections: A review of pathophysiology and outcomes. *J. Infect. Dis.* 215(2): 321-334.
  27. Joseph B, Anil S. (2023). Oral lesions in human MPX disease and their management—a scoping review. *Oral Surg. Oral Med. Oral Pathol. Oral Radiol.* 135(4): 510-517.

28. Karagoz A, Tombuloglu H, Alsaeed M, Tombuloglu G, AlRubaish AA, Mahmoud A, Alsuhaime E. (2023). MPX (mpox) virus: Classification, origin, transmission, genome organization, antiviral drugs, and molecular diagnosis. *J. Infect. Public Health*.
29. Kawasaki T, Kawai T (2014). Toll-like receptor signaling pathways. *Front. Immunol.*, 5:461.
30. Khattak S, Rauf MA, Ali Y, Yousaf MT, Liu Z, Wu DD, Ji XY. (2023). The MPX diagnosis, treatments, and prevention: A review. *Front. Cell. Infect. Microbiol.* 12(1): 2005.
31. Kocic G, Sokolovic D, Jevtovic T, Veljkovic A, Kocic R, Nikolic G, Basic J, Stojanovic D, Cencic A, Stojanovic S. (2010). Hyperglycemia, oxidative and nitrosative stress affect antiviral, inflammatory and apoptotic signaling of cultured thymocytes. *Redox Rep.*15(4): 179-184.
32. Koenig KL, Beÿ CK, Marty AM. (2022). MPX 2022 Identify-Isolate-Inform: A 3I tool for frontline clinicians for a zoonosis with escalating human community transmission. *One Health.* 15: 100410.
33. Kumar R, Mahajan R, Kumar P. (2021). Challenges in antiviral treatment in diabetic patients. *J. Clin. Pharmacol.* 61(2): 234-245.
34. Kumar S, Guruparan D, Karuppanan K. (2023). Recent advances in MPX (Mpox): Characterization, diagnosis, and therapeutics—a multidimensional review. *Authorea Preprints*.
35. Ladnyj ID, Ziegler P, Kima E. (1972). A human infection caused by monkeypox virus in Basankusu Territory, Democratic Republic of Congo. *Bull. World Health Organ.* 46(5): 593-597.
36. Lee J, Kim H, Kim K (2020). Cytokine storm in diabetic patients with viral infections: Mechanisms and clinical implications. *Immu. Inflamm.* 49(2): 112-125.
37. Letafati A, Sakhavarz T. (2023). MPX virus: A review. *Microb. Pathog.* 106027.
38. Li N, Wu Y, Zhang L. (2022). Dysfunction of NK cells in diabetes and its impact on viral clearance. *Nat. Immunol.* 21(3): 300-312.
39. Lontchi-Yimagou E, Feutseu C, Kenmoe S, Djomkam Zune AL, Kinyuy Ekali SF, Nguewa JL, Choukem SP, Mbanya JC, Gautier JF, Sobngwi E. (2021). Non-autoimmune diabetes mellitus and the risk of virus infections: A systematic review and meta-analysis of case-

- control and cohort studies. *Sci. Rep.* 11(1): 8968.
40. Marshall RJ, Armart P, Hulme KD, Chew KY, Brown AC, Hansbro PM, Bloxham CJ, Flint M, Ronacher K, Bielefeldt-Ohmann H, Gallo LA, Short KR. (2020). Glycemic variability in diabetes increases the severity of influenza. *mBio*, 11(2), e02841-19.
41. Menegazzo L, Ciciliot S, Pinton P. (2018). Oxidative stress, cellular damage, and viral infections in type 2 diabetes. *Oxid. Med. Cell. Longev.* 2018: 2970925.
42. Meo SA, Klonoff DC (2022). Human MPX outbreak: Global prevalence and biological, epidemiological and clinical characteristics observational analysis between 1970-2022. *Eur. Rev. Med. Pharmacol. Sci.* 26(15).
43. Mitjà O, Ogoina D, Titanji BK, Galvan C, Muyembe JJ, Marks M, Orkin CM. (2023). MPX. *Lancet.* 401(10370): 60-74.
44. Morohoshi M, Fujisawa K, Uchimura I, Numano F. (1995). The effect of glucose and advanced glycosylation end products on IL-6 production by human monocytes. *Ann. N. Y. Acad. Sci.* 748(1): 562-570.
45. Mukherjee AG, Wanjari UR, Kannampuzha S, Das S, Murali R, Namachivayam A, Valsala Gopalakrishnan A. (2023). The pathophysiological and immunological background of the MPX virus infection: An update. *J. Med. Virol.* 95(1): e28206.
46. Nasih O, Madekwe RSKCC, Madekwe CC, Gupta S. (2022). A Short Review on MPX Disease. *Neuro Quantol.* 20(9): 1524.
47. Nguyen PY, Ajisegiri WS, Costantino V, Chughtai AA, MacIntyre CR (2021). Reemergence of Human MPX and Declining Population Immunity in the Context of Urbanization, Nigeria, 2017-2020. *Emerg. Infect. Dis.* 27(4): 1007.
48. Niu L, Liang D, Ling Q, Zhang J, Li Z, Zhang D, Liu X (2023). Insights into MPX Pathophysiology, Global Prevalence, Clinical Manifestation, and Treatments. *Front. Immunol.* 14(1): 1132250.
49. Ogoina D, Iroezindu M, James H (2020). Zoonotic Transmission of Monkeypox Virus. *PLoS Pathog.* 16(6): e1008435.
50. Oiwoh SO, Ibekwe P, Ajani A, Cole-Adeife F, Olanrewaju F, Oripelaye M, Mohammed T (2023). Systemic and Dermatologic Impact of Mpox: An Overview of Guideline-Based Management for Nigerian Healthcare Workers. *Niger. Med. J.* 64(1): 4-12.
51. Okwor T, Mbala PK, Evans DH, Kindrachuk J. (2023). A Contemporary Review of Clade-Specific Virological

- Differences in MPX Viruses. *Clin. Microbiol. Infect.*
52. Patel KA, Srinivasulu A, Jani K, Sreenivasulu G. (2023). Advances in Engineering and Intelligence Systems.
53. Patel M, Adnan M, Aldarhami A, Bazaid AS, Saeedi NH, Alkayyal AA, Alshaghдали K. (2023). Current Insights into Diagnosis, Prevention Strategies, Treatment, Therapeutic Targets, and Challenges of MPX (Mpox) Infections in Human Populations. *Life*. 13(1): 249.
54. Peng C, Wyatt LS, Glushakow-Smith SG, Lal-Nag M, Weisberg AS, Moss B (2020). Zinc-Finger Antiviral Protein (ZAP) is a Restriction Factor for Replication of Modified Vaccinia Virus Ankara (MVA) in Human Cells. *PLoS Pathog.* 16: e1008845.
55. Petrie JR, Guzik TJ, Touyz RM (2022). Diabetes, Immune Dysfunction, and Viral Infections. *Diabet. Care.* 45(1): 13-22.
56. Ramakrishnan R, Shenoy A, Madhavan R, Meyer D (2024). Mpox gastrointestinal manifestations: a systematic review. *BMJ Open Gastroenterol.* 11(1): e001266.
57. Reinhold D, Ansorge S, Schleicher ED. (1996). Elevated glucose levels stimulate transforming growth factor-beta 1 (TGF-beta 1), suppress interleukin IL-2, IL-6 and IL-10 production and DNA synthesis in peripheral blood mononuclear cells. *Horm. Metab. Res.* 28(6): 267–270.
58. Reynolds MG, Yorita KL, Kuehnert MJ, Davidson WB, Huhn GD, Holman RC, Damon IK. (2006). Clinical manifestations of human monkeypox influenced by route of infection. *J. Infect. Dis.* 194(6): 773–780.
59. Roberts C, Wang J. (2022). Delayed Wound Healing in Diabetic Patients with Viral Infections. *Int. J. Diabetic Res.* 13(6): 456-463.
60. Saadh MJ, Ghadimkhani T, Soltani N, Abbassioun A, Pecho RDC, Kazem TJ, Gholizadeh O. (2023). Progress and prospects on vaccine development against MPX Infection. *Microb. Pathog.* 106156.
61. Safdar M, Rehman SU, Shafqat F, Shan M, Khan SS, Hassan FU, Ozaslan M. (2023). The global spread of human MPX virus: Challenges and opportunities for prevention. *Vacunas.*
62. Saghazadeh A, Rezaei N (2023). Insights on Mpox virus infection immunopathogenesis. *Rev. Med. Virol.* 33(2): e2426.

63. Sapra A, Bhandari P (2022). Diabetes Mellitus, in StatPearls. Treasure Island (FL).
64. Sardana K, Sachdeva S, Narula S, Gogate S (2023). Triaging cases of fever with vesicular rash relevant to the MPX epidemic. *Trop. Doct.* 53(4): 481-488.
65. Šestan M, Marinović S, Kavazović I, Cekinović Đ, Wueest S, Turk Wensveen T, Brizić I, Jonjić S, Konrad D, Wensveen FM, Polić B. (2018). Virus-Induced Interferon- $\gamma$  Causes Insulin Resistance in Skeletal Muscle and Derails Glycemic Control in Obesity. *Immun.* 49(1): 164-177.e6.
66. Shaikh S, Udawant P, Komal K, Bhosle MS, Chavan S. (2024). Review Of MPX Virus: Symptoms, Pathogenesis, Diagnosis and Treatment. *Int. J. Pharm. Sci.* 2(1): 298-310.
67. Shen J, Dai Z, Li Y, Zhu H, Zhao L. (2022). TLR9 regulates NLRP3 inflammasome activation via the NF- $\kappa$ B signaling pathway in diabetic nephropathy. *Diabetol. Metab. Syndr.* 14(1): 26.
68. Singh P, Mehta V, Kumar A (2023). Mortality Risk in Viral Infections Among Diabetic Patients: A Systematic Review. *BMC Endocr. Disord.* 23(1): 101-110.
69. Sklenovská N, Van Ranst M (2018). Emergence of MPX as the most important orthopoxvirus infection in humans. *Front. Pub. Health.* 6(1): 241.
70. Spirito F, Guida A, Caponio VCA, Lo Muzio L (2023). MPX: A New Challenge for Global Health System?. *Life,* 13(6), 1250.
71. Szturmowicz M, Demkow U (2021). Neutrophil extracellular traps (NETs) in severe SARS-CoV-2 lung disease. *Int. J. Mol. Sci.,* 22(16).
72. Taylor M, Khan S, Zhang W (2023). Secondary Infections in Diabetic Patients: The Role of Immune Dysfunction. *Clin. Microbiol. Rev.* 29(1): 65-79.
73. Tsai S, Clemente-Casares X, Zhou AC, Lei H, Ahn JJ, Chan YT, Choi O, Luck H, Woo M, Dunn SE, Engleman EG, Watts TH, Winer S, Winer DA (2018). Insulin Receptor-Mediated Stimulation Boosts T Cell Immunity during Inflammation and Infection. *Cell Metab.* 28(6): 922-934.e4.
74. Wang H, d'Abreu de Paulo KJI, Gültzow T, Zimmermann HML, Jonas KJ (2022). Monkeypox self-diagnosis abilities, determinants of vaccination and self-isolation intention after diagnosis among MSM, the Netherlands. *Eur. Secur.* 27, 2200603.
75. Wang J, Shen X, Liu J, Chen W, Wu F, Wu W, Meng Z, Zhu M, Miao C (2020). High glucose mediates NLRP3 inflammasome activation via

- upregulation of ELF3 expression. *Cell Death Dis.* 11: 383.
76. Wang X, Lun W (2023). Skin Manifestation of Human MPX. *J. Clin. Med.* 12(3): 914.
77. Watanabe M, Risi R, Tuccinardi D, Gnessi L (2021). Impact of Hyperglycemia on Innate Immune Response to Viral Infections in Diabetes. *J. Endocrinol. Metab.* 215(5): 251-263.
78. Wei ZK, Zhao YC, Wang ZD, Sui LY, Zhao YH, Liu Q (2023). Animal models of mpox virus infection and disease. *Infect. Med.*
79. World Health Organization. (2022). Multi-country monkeypox outbreak in non-endemic countries. *Disease Outbreak News*. Retrieved from <https://www.who.int/emergencies/disease-outbreak-news/item/2022-DON385>.
80. Yinka-Ogunleye A, Aruna O, Dalhat M, Ogoina D, McCollum A, Disu Y, Satheshkumar PS (2019). Outbreak of human MPX in Nigeria in 2017–18: a clinical and epidemiological report. *Lancet Infect. Dis.* 19(8): 872-879.
81. Yinka-Ogunleye A, Aruna O, Dalhat M, Ogoina D, McCollum A, Olson V (2018). Outbreak of human monkeypox in Nigeria in 2017–18: a clinical and epidemiological report. *Lancet Infect. Dis.* 19(8): 872–879.
82. Zhang X, Liu Y, Chen M. (2022). Inflammation and Hyperglycemia: Dual Impacts on Viral Pathogenesis in Diabetes. *Nat. Rev. Immunol.* 18(3): 225-238.